

Original Articles

## The Potential of Paraffinization Technique for Preserving Dry Biological Specimens

Takayuki MURAKAMI, Masahiro YASUDA

Department of Veterinary Anatomy, Faculty of Agriculture, University of Miyazaki

(Accepted on November 26, 2009)

**Summary :** This study evaluated the potential of the paraffinization technique, which was introduced some 80 years ago, to preserve gross biologic specimens. The paraffin-impregnated specimens were dry, odorless, of good quality, and did not deteriorate over time. Additionally, histological properties of specimens were preserved for at least 3 years. This method was simple and inexpensive, and found to be useful for both instruction and research in the fields of anatomy, pathology and zoology.

**Key words :** Dry specimen, Paraffinization technique.

### Introduction

Gross tissue specimens provide illustrative and explanatory tools in biological education and research. The ideal specimen will be dry, durable, life-like, and non-hazardous. Several methods, such as air-drying (Hamilton 1977), transparent plastic embedding (Romaniak 1946 ; Steinke *et al.* 2002), plastic coating (Church 1968 ; Updike & Hollady 1986 ; Pond *et al.* 1992), paraffinization (Hochstetter 1927 ; Blair *et al.* 1932 ; Odajima 1982), and plastination (Von Hagens 1979 ; Bickley *et al.* 1981 ; Bickley *et al.* 1987 ; Von Hagens *et al.* 1987 ; Pond *et al.* 1992 ; O'Sullivan & Mitchell 1995), have been developed for producing dry models of biological specimens. Among these methods, the plastination technique has been widely used for producing dry, flexible and durable models in anatomy, pathology and zoology. However this technique requires the purchase of expensive vacuum equipment. In an educational museum of medical school, many pathologic gross specimens are preserved by various methods ; however, paraffinized specimens are not often seen (Hirokawa *et al.* 1994). The paraffinization method, which was introduced in 1927 (Hochstetter 1927), preserves tissue by impregnating it with paraffin wax. This method is simple and

requires no expensive equipment. The purpose of this study is to revalue the paraffinization technique for the preservation of biological gross specimens.

### Materials and Methods

Hearts of cattle and whole-body specimens of small animals were used in the paraffinization technique.

All specimens for paraffinization were prepared in a manner similar to that used for microscopic paraffin embedding method. Specimens were fixed in 10 % formaldehyde solution at room temperature for several days or longer, depending on the size of the specimen. At this stage in some whole-body specimens, pin holes were made through the body walls to achieve complete formalin infiltration. Fixed and washed specimens were dehydrated and degreased in increasing concentrations of ethanol, methanol or acetone. At this time, large or whole-body specimens were evacuated in a vacuum oven to insure complete infiltration of dehydrating agents. They were then immersed in toluene with three changes of solvent. The specimens were next impregnated in melted paraffin (m. p. 57-60 °C) in the paraffin oven at 70 °C with two changes of the paraffin. After impregnation in paraffin, the speci-

mens were put in the oven, allowing excess paraffin to drain from around the specimens. After about 24 hours, the specimens were allowed to harden at room temperature. Subsequently, these paraffinized specimens were trimmed or dissected, after which they were again placed in the paraffin oven to remove coarse irregularities, and then finally cooled at room temperature.

If the color of specimens turned black during the paraffinizing process, the original paraffinized specimens were de-paraffinized successively in toluene, alcohol, and tap water. They were then bleached in hydrogen peroxide (30%), and a second paraffinization was carried out as described above.

In order to evaluate the preservation of the histological quality of the specimens, some pieces of viscera were removed from an original model paraffinized about 3 years ago. These were then immersed in melted paraffin and embedded in paraffin, sectioned at 4  $\mu\text{m}$ , and stained with hematoxylin and eosin.

## Results and Discussion

The described paraffinization technique was easy, simple and inexpensive, and required no expensive equipment, thus making this method more cost-effective. Moreover, this method appeared to be easily mastered by those with a basic knowledge of histological laboratory techniques. Additionally, this method was satisfactory and effective for the preparation of natural models of gross biologic specimens and could be used for the preservation of any of a variety of combination of tissue types.

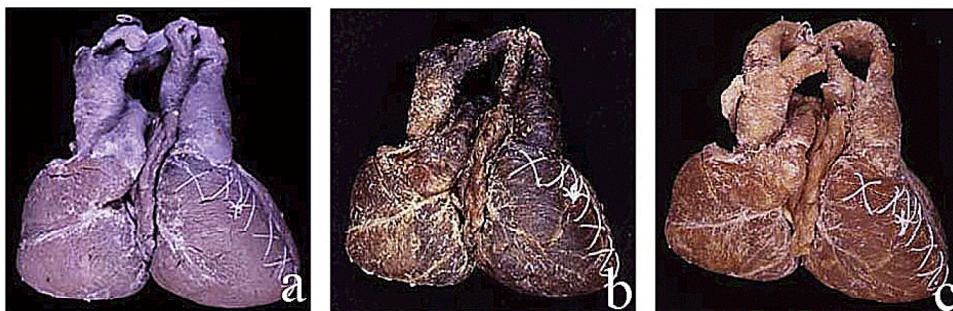
The specimens produced were dry, essentially stable and durable, and retained their original shape without major shrinkage and cleft (Fig. 1). The specimens were clean and not sticky, did not exude fumes or fluids, and were odorless, nontoxic and non-hazardous. Consequently, they could be handled di-

rectly without using gloves.

In dissected models of paraffinized whole-body specimens, the viscera and skeleton were anatomically correct and retained an appearance similar to their appearance in vivo (Fig. 2). The hollow organs, such as, gastrointestinal and female genital tracts, were clearly visible in a non-collapsed and non-dislocated state. In addition, paraffinized specimens could be used for histological investigations. Microscopic examination of pieces of the viscera from a paraffinized specimen revealed that histological details were preserved excellently for at least 3 years after paraffinization (Fig. 3). Thus, rare or unusual specimens can be made available for study when they are no longer encountered in anatomical and pathological practices.

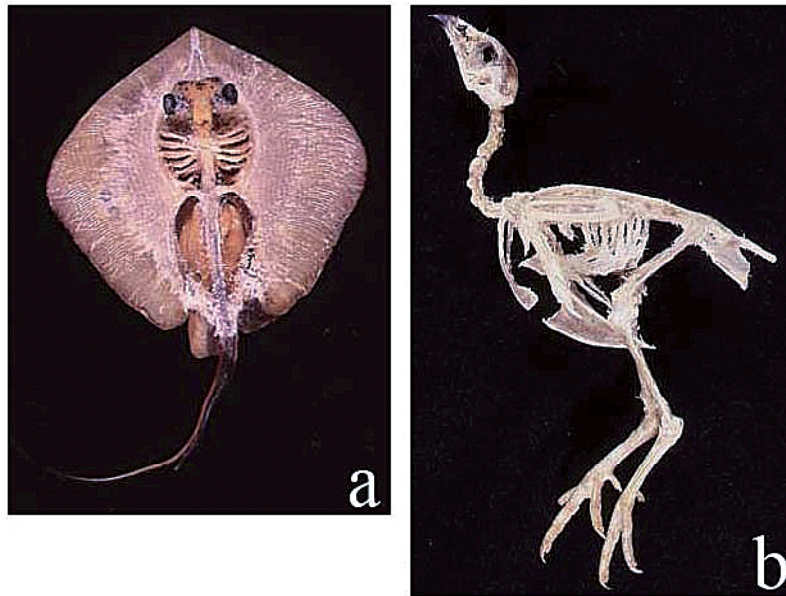
On the other hand, some paraffinized specimens that had undergone marked autolysis after death before fixation turned black. Similar color changes in specimens have been observed previously (Von Hagens 1979). However, such specimens could be bleached in hydrogen peroxide after de-paraffinization and then could be re-paraffinized (Fig. 1-c). The whole-body specimens of some fish showed a duller skin color. The black and brown colors of skin were maintained; however, the red, yellow, and blue colors disappeared during the course of dehydration in alcohol or acetone. This might be due to a technical difficulty in that those colors were possibly generated by lipid-soluble pigments within chromophores in the skin (Velando *et al.* 2006).

The paraffinized specimens could be stored at room temperature and required little storage space. They were maintenance-free, resistant to damage from insects, molds and water, and did not deteriorate with time. Moreover, these specimens will probably not undergo significant deterioration over many years of continuous use. They were also light-weight and easy to carry, and students were more enthusiastic about examining paraffinized specimens than those pre-

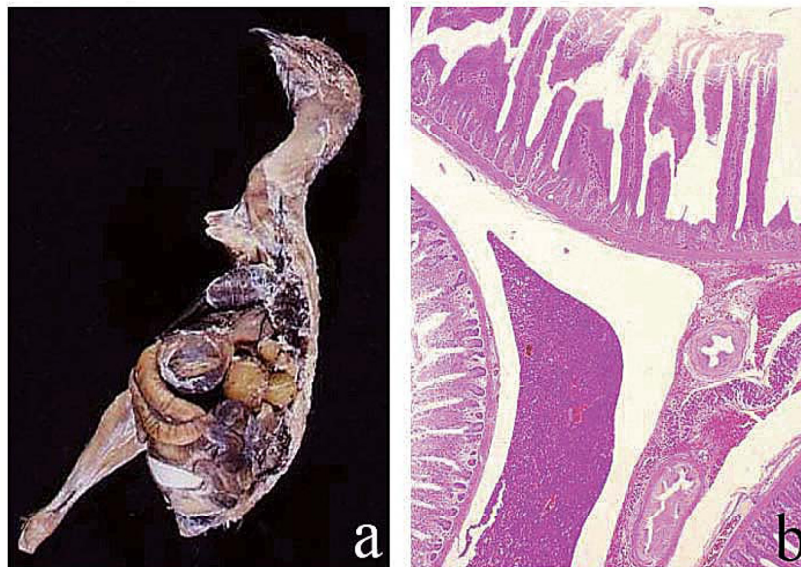


**Fig. 1.** A compound heart from a dicephalus calf.

a shows the heart after formalin fixation before methanol dehydration, b shows originally paraffinized model, and c shows re-paraffinized model after de-paraffinization and bleach.



**Fig. 2.** Paraffinized and dissected or trimmed models.  
a shows viscera and skeleton of a ray and b shows skeleton of a quail.



**Fig. 3.** Paraffinized model and its microscopical examination.  
a shows viscera of an adult female quail and b shows its histological feature.

served in formalin.

The plastination technique (Von Hagens 1979 ; Bickley *et al.* 1981 ; Bickley *et al.* 1987 ; Von Hagens *et al.* 1987 ; Pond *et al.* 1994 ; O'Sullivan & Mitchell 1995) has been widely used for producing dry models. On the other hand, although the paraffinization technique was introduced about 80 years ago (Hochstetter 1927), it has not been widely adopted (Hirokawa *et al.* 1994). We have found that the anatomical and histological qualities of paraffinized specimens have remained undamaged and unchanged in our laboratory

for at least 3 years. These high-quality paraffinized specimens were excellent illustrative and explanatory tools for biological education and research. As with the plastination technique, paraffinized specimens of high illustrative quality were found to be useful and excellent materials for teaching and research purposes.

#### Acknowledgement

This work was supported by a Grant-in-Aid from the Japan Society for the Promotion of Science (C 20580323).

## References

- Bickley, H. C., G. Von Hagens, F. M. Townsend (1981) An improved method for the preservation of teaching specimens. *Arch. Pathol. Lab. Med.* **105**, 674-676.
- Bickley, H. C., A. N. Walker, R. R. Jackson, R. S. Donner (1987) Preservation of pathology specimens by silicone plastination. *Am. J. Clin. Pathol.* **88**, 220-223.
- Blair, D. M., F. Davies, E. W. McClelland (1932) Preparation of dry specimens by paraffin-naphthalene impregnation. *J. Anat.* **66**, 486-487.
- Church, D.C. (1968) A simple method for preserving the ruminant stomach. *J. Anim. Sci.* **27**, 1525-1526.
- Hamilton, J. J. (1977) A technique for the dry preservation of functioning orthopaedic specimen. *Anat. Rec.* **189**, 201-210.
- Hirokawa, M., K. Yamashita, Y. Miyake, K. Kanahara, Y. Sakamoto (1994) Pathologic gross specimens in medical education. *Kawasaki Igakkaishi* **20** (Suppl), 41-48 (in Japanese with English summary).
- Hochstetter, F. (1927) Ueber ein Verfahren zur Herstellung von Trockenpräparaten von Tieren und Pflanzen in natürlicher Form und Farbe. *Fortschr.* **3**, 140-141.
- Odashima, G. (1982) Preparation of gross anatomy specimen. *Kaibogaku Zasshi* **57**, 399-401 (in Japanese).
- O'Sullivan E. & B.S. Mitchell (1995) Plastination for gross anatomy teaching using low cost equipment. *Surg. Radiol. Anat.* **17**, 277-281.
- Pond, K. R., S. D. Hollanday, J. -M. Luginbuhl (1992) Preservation of tissues and gastrointestinal tract portions by plastic coating or plastination. *J. Anim. Sci.* **70**, 1011-1014.
- Romaniak, T. H. (1946) The use of unsaturated polyester resins for embedding biological material. *Science* **104**, 601-602.
- Steinke, H., S. Pfeiffer, K. Spanel-Borowski (2002) A new plastination technique for head slices containing brain. *Ann. Anat.* **184**, 353-358.
- Udike, S.J. & S.D. Holladay (1986) Preparation of flexible models of hollow gastrointestinal organs. *Anat. Rec.* **216**, 207-210.
- Velando, A., R. Beamonte-Barriento, R. Torres (2006) Pigment-based skin colour in the blue-footed booby. *Oecologia*, **149**, 535-542.
- Von Hagens, G. (1979) Impregnation of soft biological specimens with thermosetting resins and elastomers. *Anat. Rec.* **194**, 247-256.
- Von Hagens, G., K. Tiedemann, W. Kriz (1987) The current potential of plastination. *Anat. Embryol.* **175**, 411-421.

## 乾燥生物標本作製のためのパラフィン浸透法の可能性

村上隆之・保田昌宏

宮崎大学農学部獣医解剖学講座

### 要約

約80年前に紹介された肉眼的生物標本保存法であるパラフィン浸透法の可能性について調べた。本法は組織にパラフィンを浸透させて保存する方法である。作製した標本は乾燥しており、無臭で耐久性があり、高品質で劣化しなかった。さらに、それらの組織学的構造は少なくとも3年間は維持されていた。本法は簡単で安価であり、解剖学や病理学、動物学の分野における教育と研究に有効であることが認められた。

キーワード：乾燥標本, パラフィン浸透法