

**NOTE Pathology****Immunohistochemical Analysis of Cyclins in Canine Normal Testes and Testicular Tumors**Yuichi MURAKAMI<sup>1)</sup>, Susumu TATEYAMA<sup>1)\*</sup>, Kazuyuki UCHIDA<sup>1)</sup> and Ryoji YAMAGUCHI<sup>1)</sup><sup>1)</sup>Department of Veterinary Pathology, Faculty of Agriculture, Miyazaki University, Nishi 1-1, Gakuen Kibana Dai, Miyazaki 889-2192, Japan

(Received 13 December 2000/Accepted 11 April 2001)

**ABSTRACT.** The expression of cyclins A, D1, D2 and E were examined immunohistochemically in 5 canine normal testes and 31 testicular tumors, including 14 seminomas, 11 Sertoli cell tumors and 6 Leydig cell tumors. In canine normal testes, cyclin A expression was detected in spermatogonia and primary spermatocytes. This suggests that A-type cyclins may play some role in canine spermatogenesis. Cyclin A expression was also observed in 13/14 (92.9%) seminomas and 2/11 (18.2%) Sertoli cell tumors, but no positive reaction was observed in Leydig cell tumors. Parallel examinations for cyclins D1, D2 and E gave negative results in canine normal testes and testicular tumors. High levels of cyclin A expression in canine seminomas indicate that the neoplastic germ cells may be arrested at the spermatogonia and primary spermatocyte stages of differentiation.

**KEY WORDS:** canine, cyclin, seminoma.*J. Vet. Med. Sci.* 63(8): 909-912, 2001

Primary testicular tumors occur most commonly in aged dogs. The principal tumors of the canine testes are seminoma, Sertoli cell tumor, and Leydig (interstitial) cell tumor. Usually, they occur with almost equal frequency, although the frequency varies slightly among reports [13].

Cyclins are prime cell cycle regulators, which are central to the control of major checkpoints in eukaryotic cells. Cyclins are thought to be activated by forming a complex with cyclin-dependent kinases (cdk) at various stages of the cell cycle, and these promote cell cycle progression. The involvement of several cyclins in human cancer has been recognized in the last several years [6].

The mammalian A-type cyclin family consists of two members, cyclins A1 and A2. Cyclin A1, which is newly discovered, is expressed in human testes at high levels and also in certain myeloid leukemia cells [16, 17], and is thought to act in the meiotic cell cycle [14]. Cyclin A2 functions in somatic cells, and promotes both G1/S and G2/M transitions [11]. The mammalian D-type cyclin family consists of three members, cyclins D1, D2 and D3. Cyclin D1 qualifies as a protooncogene, which is overexpressed in a wide range of malignancies in human tumors [6]. Cyclin D2 has recently been identified as a candidate protooncogene activated in subsets of testicular and ovarian germ cell tumors [2, 7, 15]. Cyclin E has been shown to correlate with progression in significant subsets of germ cell tumors [3, 4]. However, there has been no research on cyclins in canine testicular tumors. To determine their expression patterns in relation to cell type, proliferation, differentiation and tumorigenesis, we examined immunohistochemically the expression of cyclins A, D1, D2 and E in canine normal testes and testicular tumors.

A total of 31 canine testicular tumors were obtained from surgical specimens between 1996 and 2000 at the Department of Veterinary Pathology, Miyazaki University, Japan. Five normal canine testes were obtained from dogs without testicular tumors. For histopathology, the specimens were fixed in 10% neutral buffered formalin and embedded in paraffin. Paraffin sections cut at 4  $\mu$ m thick were stained with hematoxylin and eosin (HE) for light microscopy. The pathology of 31 cases is listed in Table 1. The 31 canine testicular tumors comprised 14 seminomas (2 intratubular and 12 diffuse types), 11 Sertoli cell tumors (8 intratubular and 3 diffuse types) and 6 Leydig cell tumors. The primary antibodies used were rabbit polyclonal antibodies against human cyclin A (H-432, Santa Cruz. Biotech., CA, U.S.A), human cyclin D1 (H-295, Santa Cruz. Biotech.), human cyclin D2 (H-289, Santa Cruz. Biotech.) and cyclin E of rat origin (M-20, Santa Cruz. Biotech.). Immunohistochemistry was performed by using an Envision polymer reagent (DAKO, Kyoto, Japan). Hydrated autoclave treatment was performed on the paraffin sections before immunostaining. Endogenous peroxidase was quenched by 0.3% hydrogen peroxide in methanol for 30 min at room temperature. The sections were incubated with 3%(w/v) bovine serum albumin in PBS for 1 h at 37°C. Primary antibodies against cyclin A (1:40), cyclin D1 (1:40), cyclin D2 (1:40) and cyclin E (1:100) were applied. The sections were incubated with these primary antibodies overnight at 4°C, and then incubated with Envision polymer reagent for 30 min at 37°C. The chromogenic reaction was carried out with 3,3'-diaminobenzidine-4 HCl (0.5 mg/ml) in Tris-hydrochloride buffer, pH 7.6, supplemented with 0.03%(v/v) hydrogen peroxide, and the sections were counterstained with Mayer's hematoxylin.

We evaluated protein expression in the germ cells, Sertoli cells, and Leydig cells of canine normal testes, and in the tumor cells of seminomas, Sertoli cell tumors, and Leydig

\* CORRESPONDENCE TO: TATEYAMA, S., Department of Veterinary Pathology, Faculty of Agriculture, Miyazaki University, Miyazaki 889-2192, Japan.

Table 1. Expression of cyclins A, D1, D2 and E in canine normal testes and testicular tumors

Tissues and tumors (numbers)	Percentage of positive cases			
	Cyclin A	Cyclin D1	Cyclin D2	Cyclin E
Normal testis (5)				
Germ cell	100.0%	0.0%	0.0%	0.0%
Sertoli cell	0.0%	0.0%	0.0%	0.0%
Leydig cell	0.0%	0.0%	0.0%	0.0%
Seminoma (14)	92.9%	0.0%	0.0%	0.0%
Intratubular type (3)	100.0%			
Diffuse type (11)	90.9%			
Sertoli cell tumor (11)	18.2%	0.0%	0.0%	0.0%
Intratubular type (8)	12.5%			
Diffuse type (3)	33.3%			
Leydig cell tumor (6)	0.0%	0.0%	0.0%	0.0%

cell tumors, respectively. The results of immunohistochemistry were assessed using a grading system based on the percentage of positive nuclei. The immunostaining was scored as 0, 0–9% of the nuclei stained; 1, 10–39% of the nuclei stained; 2, 40–60% of the nuclei stained. Specimens assigned scores of 1 and 2 were considered positive.

The immunohistochemical data for cyclins A, D1, D2 and E are summarized in Table 1, and the detailed data showing the percentage of cells positive for cyclin A are described in Table 2.

In canine normal testes, cyclin A expression was detected in the nuclei of spermatogonia and primary spermatocytes at most stages of the seminiferous epithelium cycle (Fig. 1). The intense staining of these cells persisted to the first meiotic division. Cyclin A protein was not detected in the Sertoli and Leydig cells of canine normal testes (Table 1). Cyclin D1, D2 and E proteins were not detected in any testicular elements (Table 1).

In canine testicular tumors, a positive reaction for cyclin A was observed in 13/14 (92.9%) seminomas and 2/11 (18.2%) Sertoli cell tumors, but was not observed in Leydig cell tumors (Table 1). Most canine seminomas had intense nuclear reactivity for cyclin A (Fig. 2), and granular staining of cyclin A was found in the cytoplasm of the neoplastic germ cells in one case (Fig. 3). The percentage of cells positive for cyclin A was very high in canine seminomas (Table 2). In addition, relative to normal germ cells, canine seminomas showed similar proportions of positive cells and levels of cyclin A. Canine Sertoli cell tumors had scattered nuclear reactivity for cyclin A (Fig. 4), but the percentage of positive neoplastic cells was much lower than that in the seminomas (Table 2). There was no difference in immunoreactivity for cyclin A between intratubular and diffuse types in both canine seminomas and Sertoli cell tumors. Parallel examinations with antibodies against cyclins D1, D2 and E gave consistently negative results in all 31 canine testicular tumors (Table 1).

In humans and mice, the cyclin A1 is present only in male germ cells just prior to or during the first meiotic division, and is thought to function in the meiotic cell cycle [3, 14].

Table 2. Percentage of cells positive for cyclin A in canine normal testes and testicular tumors

Tissues and tumors (numbers)	Percentage of cells positive for cyclin A		
	0–9	10–39	40–60
Normal testis (5)			
Germ cell	0	5	0
Sertoli cell	5	0	0
Leydig cell	5	0	0
Seminoma (14)	1	9	4
Intratubular type (3)	0	2	1
Diffuse type (11)	1	7	3
Sertoli cell tumor (11)	9	2	0
Intratubular type (8)	7	1	0
Diffuse type (3)	2	1	0
Leydig cell tumor (6)	6	0	0

By contrast, the cyclin A2 is expressed in the spermatogonia and in highest levels in preleptotene spermatocytes, and is likely to act during mitosis in the stem cell stage of spermatogenesis [14]. Their previous investigations are consistent with our observations on cyclin A expression in the spermatogonia and the primary spermatocytes of canine normal testes. Therefore, our results suggest that A-type cyclins may play some role in canine spermatogenesis. However, it is uncertain whether the cyclin A protein detected in the present cases was cyclin A1 or A2, because the cyclin A antibody used recognizes two types of cyclin A. Therefore, further immunohistochemical approaches using antibodies specific for cyclin A1 and A2 are needed to determine the localization of their proteins in canine normal testes.

Our results on canine testicular tumors demonstrated that cyclin A was expressed at high levels in the most of canine seminomas. This finding was consistent with the results of previous investigations on cyclin A1 expression in human seminomas [3, 4]. Since cyclin A expression was also detected in the germ cells of canine normal testes, we concluded that the cyclin A expression in canine seminomas had little relation to the tumorigenesis. One plausible explanation for cyclin A expression in canine seminomas could

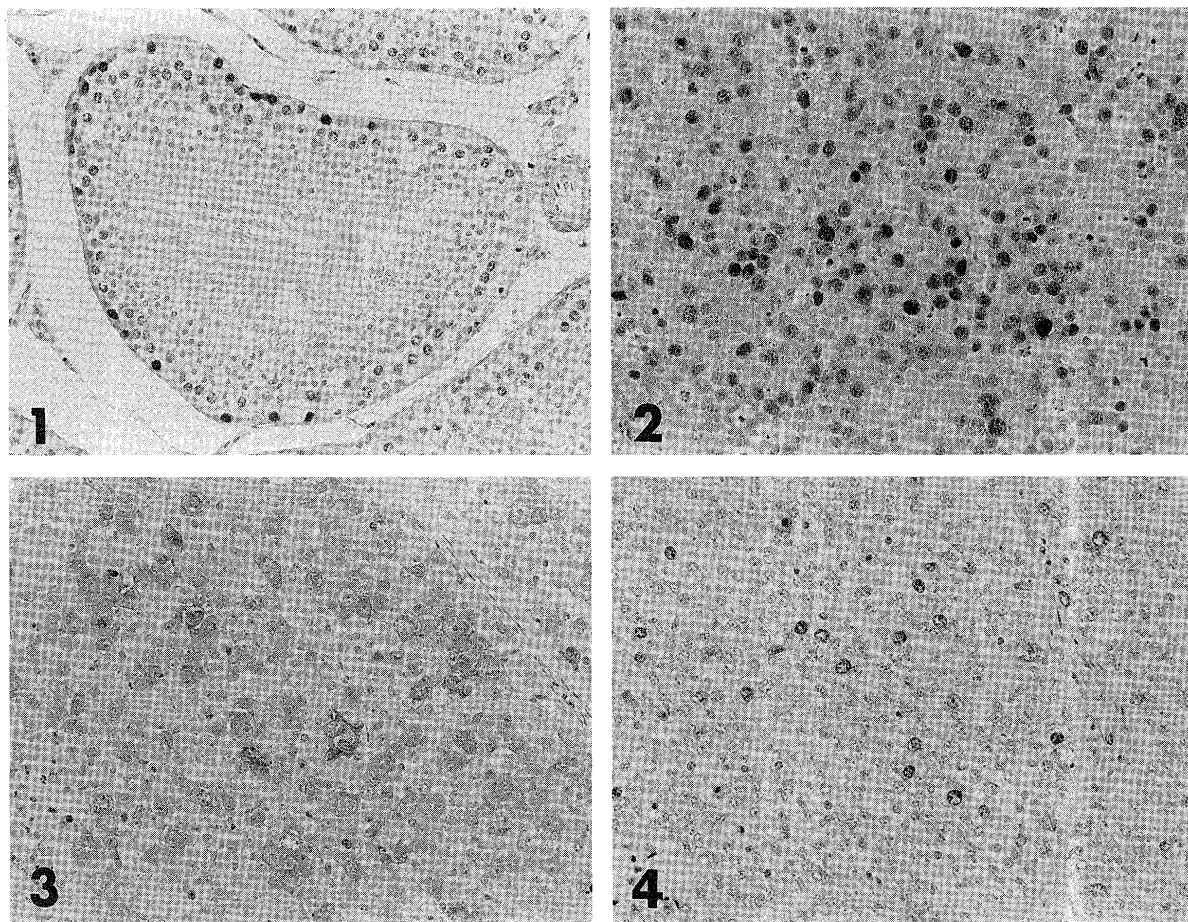


Fig. 1. Immunoreactivity of canine normal testis for cyclin A. Spermatogonia and primary spermatocytes show intense nuclear staining.  $\times 250$ .

Fig. 2. Immunoreactivity of canine seminoma for cyclin A. Neoplastic germ cells show intense nuclear staining.  $\times 250$ .

Fig. 3. Immunoreactivity of canine seminoma for cyclin A. Neoplastic germ cells show granular cytoplasmic staining.  $\times 250$ .

Fig. 4. Immunoreactivity of canine Sertoli cell tumor for cyclin A. Neoplastic Sertoli cells show scattered nuclear staining.  $\times 250$ .

be that the neoplastic germ cells reflect the level of expression of cyclin A of their normal counterpart at the same stages of spermatogenetic development. That is to say, the neoplastic germ cells in canine seminomas may be arrested at the spermatogonia and primary spermatocyte stages of differentiation. In one canine seminoma, cyclin A expression was found in the cytoplasm of the neoplastic germ cells, although cyclin A is usually expressed in the nucleus. There is a similar report concerning cytoplasmic staining of cyclin A in human renal cell cancers [1]. In addition, we also reported previously that cytoplasmic staining of cyclin A was observed in canine squamous cell carcinomas [10]. However, it is unclear the reason why cyclin A was expressed in the cytoplasm of their tumors.

There are several reports that cyclin D2 overexpression is an early event in human male germ cell tumorigenesis [2, 7]. In addition, very recent studies have suggested that cyclin E immunoreactivity is correlated with the progression of human seminomas [3, 4]. In this study, all the canine seminoma cases were negative for cyclins D2 and E. Our find-

ings of no expression of cyclin D2 and E in canine seminomas suggest that neither of these two cyclins is involved in the tumorigenesis. However, a possibility remains that human cyclin D2 antibody used in this study had a reduced affinity for canine tissues, since we could not confirm the cross-reactivity with canine cyclin D2. It has been confirmed that cyclin D1 expression is absent in human seminomas [2], in contrast to the elevated expression of cyclins D2 and E. That report was consistent with our observation that cyclin D1 expression was not detectable in canine seminomas.

To our knowledge, there has been no report demonstrating significant overexpression of cyclins in Sertoli cell and Leydig cell tumors, and our immunohistochemical analyses of cyclins supported this. Although cyclin A was expressed slightly in a minority of the canine Sertoli cell tumors, the percentage of cells positive for cyclin A was much lower than that in the canine seminomas. The cyclin A expression in canine Sertoli cell tumors probably reflects only elevated tumor proliferation (cyclin A being an integral component

of the cell cycle). It has been reported that canine Sertoli cell and Leydig cell tumors are endocrinologically active for several hormones, including estrogen [12]. Thus, their tumorigenesis is likely to correlate with hormone concentrations rather than alterations of cell cycle regulators such as cyclin and cdk.

## REFERENCES

1. Aaltomaa, S., Lipponen, P., Ala-Opas, M., Eskelinen, M., Syrjanen, K. and Kosma, V. M. 1999. *Br. J. Cancer* **80**: 2001–2007.
2. Bartkova, J., Rajpert-de, Meyts, E., Skakkebaek, N. E. and Bartek, J. 1999. *J. Pathol.* **187**: 573–581.
3. Bartkova, J., Thullberg, M., Rajpert-de, Meyts, E., Skakkebaek, N. E. and Bartek, J. 2000. *Int. J. Cancer* **85**: 370–375.
4. Datta, M. W., Renshaw, A. A., Dutta, A., Hoffman, M. A. and Loughlin, K. R. 2000. *Mod. Pathol.* **13**: 667–672.
5. Dobashi, Y., Shoji, M., Jiang, S. X., Kobayashi, M., Kawakubo, Y. and Kameya, T. 1998. *Am. J. Pathol.* **153**: 963–972.
6. Hall, M. and Peters, G. 1996. *Adv. Cancer Res.* **68**: 67–108.
7. Houldsworth, J., Reuter, V., Bosl, G. J. and Chaganti, R. S. 1997. *Cell Growth Differ.* **8**: 293–299.
8. Huuhtanen, R. L., Blomqvist, C. P., Bohling, T. O., Wiklund, T. A., Tukiainen, E. J., Virolainen, M., Tribukait, B. and Andersson, L. C. 1999. *Cancer Res.* **59**: 2885–2890.
9. Liu, D., Matzuk, M. M., Sung, W. K., Guo, Q., Wang, P. and Wolgemuth, D. J. 1998. *Nat. Genet.* **20**: 377–380.
10. Murakami, Y., Tateyama, S., Rungsipipat, A., Uchida, K. and Yamaguchi, R. 2000. *J. Vet. Med. Sci.* **62**: 743–750.
11. Pagano, M., Pepperkok, R., Verde, F., Ansorge, W. and Draetta, G. 1992. *EMBO J.* **11**: 961–971.
12. Peters, M. A., de Jong, F. H., Teerds, K. J., de Rooij, D. G., Dieleman, S. J. and van Sluijs, F. J. 2000. *J. Endocrinol.* **166**: 153–161.
13. Pulley, L. T. and Stannard, A. A. 1990. pp. 45–48. *In: Tumors in Domestic Animals*, 2nd ed. (Moulton, J. E. ed.), Univ. California Press, Berkeley.
14. Ravnik, S. E. and Wolgemuth, D. J. 1999. *Dev. Biol.* **207**: 408–418.
15. Sicinski, P., Donaher, J. L., Geng, Y., Parker, S. B., Gardner, H., Park, M. Y., Robker, R. L., Richards, J. S., McGinnis, L. K., Biggers, J. D., Eppig, J. J., Bronson, R. T., Elledge, S. J. and Weinberg, R. A. 1996. *Nature (Lond.)* **384**: 470–474.
16. Yang, R., Morosetti, R. and Koeffler, H. P. 1997. *Cancer Res.* **57**: 913–920.
17. Yang, R., Nakamaki, T., Lubbert, M., Said, J., Sakashita, A., Freyaldenhoven, B. S., Spira, S., Huynh, V., Muller, C. and Koeffler, H. P. 1999. *Blood* **93**: 2067–2074.