

Available online at [www.sciencedirect.com](http://www.sciencedirect.com)

ScienceDirect

journal homepage: [www.elsevier.com/locate/radcr](http://www.elsevier.com/locate/radcr)

## Case Report

# Postmortem computed tomography of barium peritonitis due to descending colon perforation <sup>☆</sup>

Norihiro Shinkawa, MD, PhD<sup>a,b,\*</sup>, Mitsuro Yanagita, MD, PhD<sup>c</sup>, Nobuhiro Yukawa, MD, PhD<sup>a</sup>, Tatsuhiro Nagatomo, MD<sup>b</sup>

<sup>a</sup> Section of Legal Medicine, Department of Social Medicine, Faculty of Medicine, University of Miyazaki, Miyazaki, Japan

<sup>b</sup> Radiology Division, Faculty of Medicine, University of Miyazaki Hospital, Miyazaki, Japan

<sup>c</sup> MK Clinic, Miyakonojo, Miyazaki, Japan

## ARTICLE INFO

## Article history:

Received 9 September 2023

Revised 1 February 2024

Accepted 5 February 2024

## Keywords:

Barium

Colon

Diverticulum

Peritonitis

Tomography

## ABSTRACT

We describe herein the findings from postmortem computed tomography (PMCT) of barium peritonitis due to descending colon perforation. The patient was a woman in her 60s who underwent upper gastrointestinal series with barium swallow for the purpose of physical examination. The patient developed abdominal pain the next day and visited a clinic, but was sent home for later follow-up. She was found dead at home 8 days after upper gastrointestinal series. Based on the corpse phenomena and police investigations of the scene of death, the patient was estimated to have died 6 days after the upper gastrointestinal series. PMCT revealed free gas within the peritoneal cavity. Barium and fat stranding were also observed around a diverticulum in the descending colon. A large amount of residual barium was seen in the ascending colon and was considered to represent antemortem constipation and delayed barium excretion. No gas was detected in the abdominal wall, cardiac chambers or hepatic vasculature. The pancreas and adrenal glands had a normal appearance. We diagnosed barium peritonitis due to descending colon perforation as the cause of death. Diverticular perforation was suspected because barium retention and fat stranding were particularly noticeable around the descending colon diverticulum. In conclusion, we have presented a rare case of postmortem diagnosis of barium peritonitis. In PMCT interpretation, distinguishing between ante- and postmortem intestinal perforations is important.

© 2024 The Authors. Published by Elsevier Inc. on behalf of University of Washington.

This is an open access article under the CC BY-NC-ND license

(<http://creativecommons.org/licenses/by-nc-nd/4.0/>)

<sup>☆</sup> Competing Interests: The authors declare that they have no known competing financial interests or personal relationships that could have appeared to influence the work reported in this paper.

\* Corresponding author.

E-mail address: [norihiro\\_shinkawa@med.miyazaki-u.ac.jp](mailto:norihiro_shinkawa@med.miyazaki-u.ac.jp) (N. Shinkawa).

<https://doi.org/10.1016/j.radcr.2024.02.008>

1930-0433/© 2024 The Authors. Published by Elsevier Inc. on behalf of University of Washington. This is an open access article under the CC BY-NC-ND license (<http://creativecommons.org/licenses/by-nc-nd/4.0/>)

---

## Introduction

Even with the development of gastrointestinal endoscopy, gastrointestinal contrast study remains an indispensable diagnostic tool. With gastrointestinal contrast studies, barium peritonitis due to intestinal perforation is known as a complication of barium enema and the upper gastrointestinal series with barium swallow. Incidences of 2–4 per 10,000 [1] and 2–8 per 10,000 [2] have been reported for barium enema, compared to 3 per 1,013,000 for upper gastrointestinal series [3].

Various mortality rates for barium peritonitis have been reported, such as 22.2% [4], 29% [5], and 35% [2]. If left untreated, the mortality rate is 100% [6]. Early surgical intervention could diminish the intensity of inflammation and improve outcomes [7].

We report a case in which the patient was found dead and for whom the cause of death was diagnosed as barium peritonitis based on antemortem information and postmortem computed tomography (PMCT). The take-away lesson from this case was the importance of checking for gas in the abdominal wall, cardiac chambers, and hepatic vasculature to differentiate pathological (antemortem) intestinal perforation from postmortem decomposition or gastromalacia on PMCT. In addition, clinically, barium peritonitis should be included among the differential diagnoses for abdominal pain after upper gastrointestinal series with barium swallow.

---

## Case report

### Case history

The patient was a woman in her 60s who underwent upper gastrointestinal series with barium swallow for the purpose of general physical examination. The patient had no particular symptoms. The course is described below, taking the day of barium swallow as day 0.

On day 1, the patient visited a local clinic with abdominal pain. Abdominal ultrasonography and urinalysis were performed, but showed no abnormalities. On day 5, she returned with diarrhea. Stool examination found no abnormalities, so she was followed-up. On day 8, the patient was found dead in her home. Based on corpse phenomena and police investigations of the scene of death, the patient was estimated to have died on day 6. The above clinical information was not obtained directly from the local clinic, but was provided by the police following an investigation. The clinical information we had access to was thus limited. As far as we know, the patient had no specific contributory genetic information, family history, comorbidities, or medical history.

In our jurisdiction, the police decide whether a forensic autopsy is necessary based on the external findings of the corpse, PMCT findings and the outcomes of the police investigation. Although PMCT is not a perfect alternative to full postmortem examination, autopsies can be avoided if involvement by a third party is not suspected and if the cause and manner of death can be reasonably explained based on PMCT findings

and the results of the police investigation [8]. In the present case, no forensic autopsy was performed.

### Findings from PMCT

On day 9, PMCT was performed about 1 day after the deceased was found and 4 days after she was last seen alive.

Free gas was noted within the peritoneal cavity (Fig. 1A and B). Multiple diverticula were found in the descending and sigmoid colon (Fig. 1C and D). High-attenuation fluid and fat stranding were observed around a diverticulum in the descending colon (Fig. 1E–G). Peritoneal thickening was also seen in the right abdomen (Fig. 1F). High-attenuation fluid was found not only around the descending colon, but also in the upper abdomen and pelvis (Fig. 1A and H). The ascending colon was dilated, containing a large amount of high-attenuation fluid (Fig. 1G). Blood in the great vessels showed clotting conforming to the shape of the vessel (Fig. 1I).

No gas was detected in the abdominal wall, cardiac chambers or hepatic vasculature (Fig. 2A–C). Pancreas and adrenal glands appeared normal (Fig. 2D–F). Other than the above abdominal findings, no trauma or endogenous disease was observed.

Written consent was obtained from a close relative of the patient for publication of the case information.

---

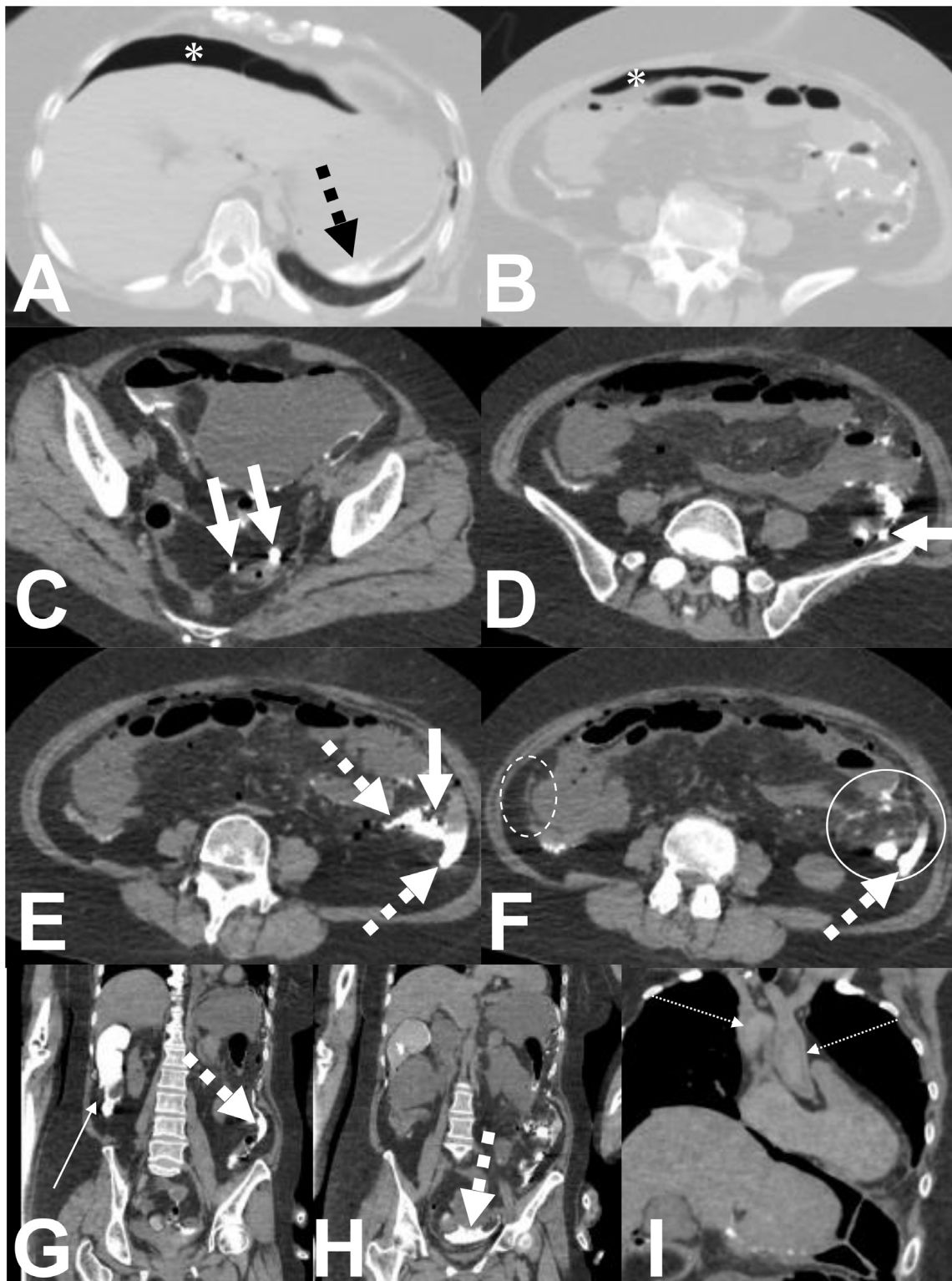
## Discussion

We diagnosed the cause of death as barium peritonitis due to perforation of the descending colon. In particular, diverticular perforation was suspected because barium retention and fat stranding were noticeable around the descending colon diverticulum.

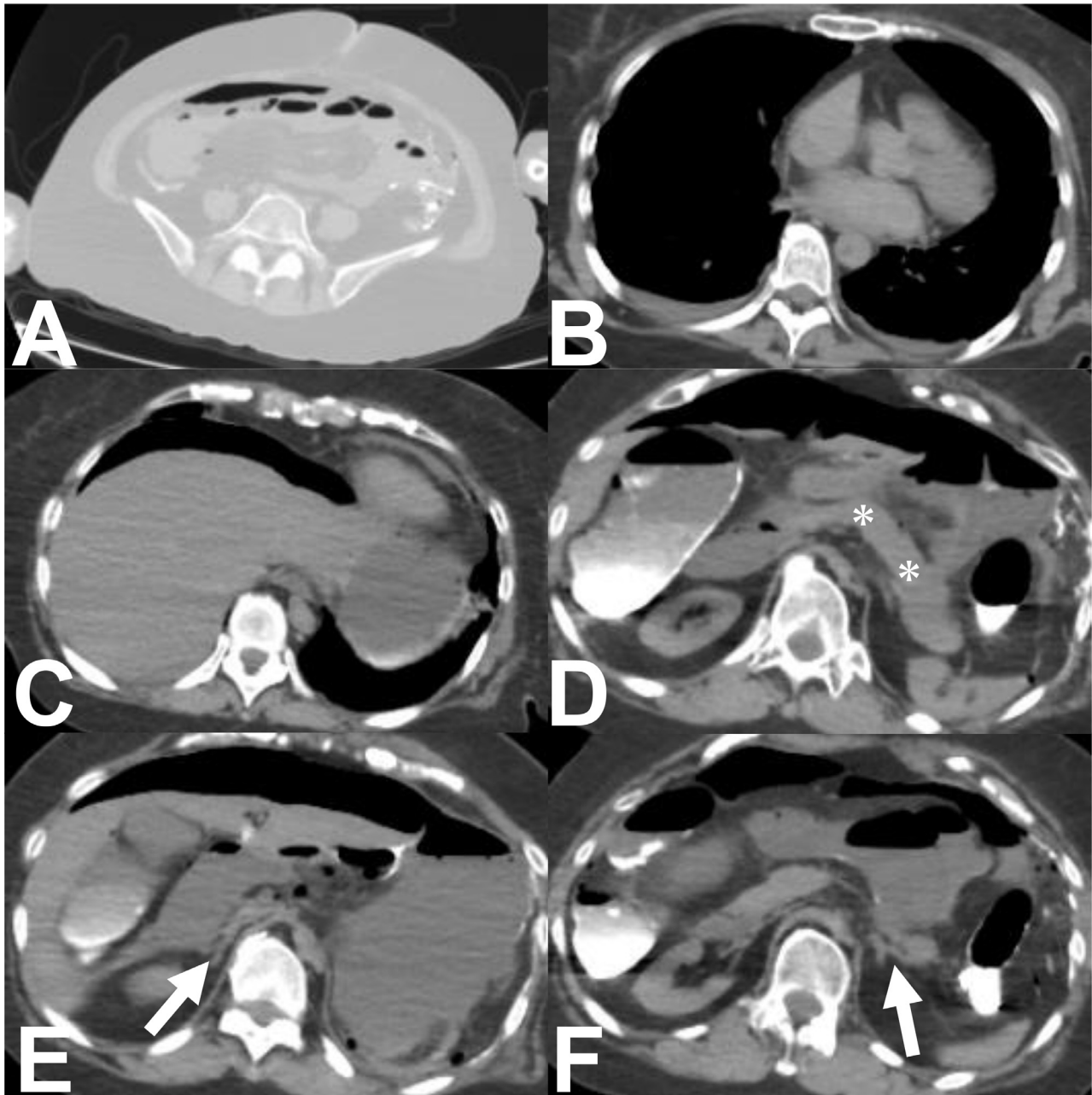
Although diagnosis of barium peritonitis is easy with evidence of extraintestinal barium in clinical settings [4], free gas in the peritoneal cavity on PMCT must be interpreted with caution [9]. In the absence of penetrating injury or resuscitative measures, free gas in the peritoneal cavity on PMCT could be due to decomposition, gastromalacia, or pathological (antemortem) bowel perforation. If putrefaction is responsible, then gas may also be detected in the abdominal wall, cardiac chambers or hepatic vasculature [9]. In the present case, no gas was detected in the abdominal walls, cardiac chambers or hepatic vasculature (Fig. 2A–C).

The pancreas and adrenal glands are among the earliest internal organs to undergo autolysis, but generally appear normal on PMCT until putrefactive gas is present [10]. In the present case, the pancreas and adrenal glands appeared normal (Fig. 2D–F).

Free gas in the present case was thus considered to represent pathological (antemortem) bowel perforation. Free or localized high-attenuation fluid collections in the peritoneal cavity, abdominal fat stranding, and peritoneal thickening were considered to represent reactive peritonitis rather than artifactual gastromalacia with perforation [9]. In the present case, blood in the great vessels showed clots conforming to the shape of the vessels. Clotting in the great vessels suggested



**Fig. 1** – Postmortem CT images. A, B) Lung setting axial images (window level [WL]: -400 HU, window width [WW]: 1500). Asterisks indicate free gas in the peritoneal cavity. C–F) Abdominal setting axial images (WL: 40, WW: 440). G–I) Abdominal and mediastinal setting coronal images (WL: 40, WW: 440). Thick dashed arrows indicate high-attenuation fluid (Fig. A, E–H). Thick arrows indicate diverticula of the colon (Fig. C–E). Circle indicates fat stranding (Fig. F). Dashed circle indicates peritoneal thickening (Fig. F). Thin arrow indicates that the ascending colon was dilated to contain a large amount of high-attenuation fluid (Fig. G). Dashed thin arrows indicate the clotted blood in the great vessels that conforms to the shape of the vessel (Fig. I).



**Fig. 2 – Postmortem CT axial images. A)** Axial image of the lung (WL: -400, WW: 1500). **B-F)** Axial images of the mediastinal and abdomen (WL: 40, WW: 440). No gas detected in the abdominal wall (Fig. A), cardiac chambers (Fig. B) or hepatic vasculature (Fig. C). Asterisks indicate pancreas (Fig. D), and arrows indicate adrenal glands (Fig. E and F). Pancreas and adrenal glands have a normal appearance.

chronic death [11]. If the clot conforms to the shape of the vessel, clotting likely occurred postmortem [12].

An autopsy case of sigmoid colon perforation after barium gastrography has been reported [13], but PMCT was not performed in that case. Forensic autopsy was performed and barium peritonitis was diagnosed by analysis using energy-dispersive X-ray fluorescence spectrometry of the peritoneal cavity contents. In the present case, from the history of upper gastrointestinal series with barium swallow, there is no doubt that the high-attenuation fluid was barium. This is the first

case in which barium peritonitis has been diagnosed as the cause of death by PMCT.

In 1916, Rosenthal reported the first case of barium peritonitis from acute perforation of a duodenal ulcer after an upper gastrointestinal series complicated by intestinal obstruction [6].

Gastrointestinal contrast studies include barium enema and upper gastrointestinal series. The site of gastrointestinal perforation is in the large intestine in 77.8% [4] and in the sigmoid colon in 70% [14], overwhelmingly more often than in the



stomach or duodenum. About half of these represent colonic perforations after upper gastrointestinal series [5]. Perforated sites are reported to be vulnerable sites such as gastric ulcers, ulcerative colitis, and colonic diverticula [4,5]. Catheter-induced colonic mucosal injury during barium enema has also been described [4,5]. These sites are perforated by increased intestinal pressure from barium and air. Even in the normal colon without these diseases, a hard barium fecal mass can cause laceration to the colonic wall [15] or ischemic necrosis [16] and perforation.

The duration from barium contrast examination to onset has been reported as within 5 days in 76% of cases [5], with mean durations such as 3.4 days [14] and 3.2 days [17]. Although the timing of the onset of barium peritonitis could not be specified in the present case, the patient was presumed to have died on day 6, and onset was thus within 5 days, as reported in many cases.

Risk factors for gastrointestinal perforation after a gastrointestinal contrast study have been reported to include old age, constipation, colonic diverticulum, ulcerative colitis, and colon cancer [4,5]. In the present case, colonic diverticulum applied. PMCT also showed a large amount of residual barium in the ascending colon, which was attributed to antemortem constipation and delayed barium excretion. No reports have described colonic diverticulum or constipation in the medical interview before the upper gastrointestinal series. Potential countermeasures to this situation could include identifying risk factors through thorough interviews, substituting other investigations for upper gastrointestinal endoscopy, and encouraging patients to take laxatives and drink fluids after the examination [3].

In conclusion, we have presented a rare case of postmortem diagnosis of barium peritonitis. In PMCT interpretation, distinguishing between ante- and postmortem intestinal perforations is important. The take-away lesson from this case was the importance of checking for gas in the abdominal wall, cardiac chambers, and hepatic vasculature to differentiate pathological (antemortem) intestinal perforation from postmortem decomposition or gastromalacia on PMCT. In addition, clinically, barium peritonitis should be included among the differential diagnoses for abdominal pain after upper gastrointestinal series with barium swallow.

## Patient consent

Written consent was obtained from a close relative of the patient for publication of the case information.

## REFERENCES

[1] Gardiner H, Miller RE. Barium peritonitis, a new therapeutic approach. *Am J Surg* 1973;125(3):350–2. doi:10.1016/0002-9610(73)90059-7.

[2] Tai C-J, Wang W, Huang YM. Barium meal peritonitis, fatal outcome in unsuspected small bowel perforation. *Indian J Surg* 2021;83(6):1589–90. doi:10.1007/s12262-020-02711-z.

[3] Shibuya D, Konno Y, Aida S, Kato K, Shimada T. Complications of gastric mass screening by indirect fluororadiography. *Nihon Sokaki Gan Kenshin Gakkai Zasshi (J Gastrointestinal Cancer Screen)* 2006;44(3):251–8 [in Japanese]. doi:10.11404/jsgcs2006.44.3\_251.

[4] Ikezawa T, Hasegawa H, Maeda S, Nakagami K, Nakata Y, Joh T, et al. Two cases of barium peritonitis. *Nihon Rinsho Geka Igakkai Zasshi (J Jpn Prac Surg Soc)* 1983;44(12):1477–82 [in Japanese]. doi:10.3919/ringe1963.44.1477.

[5] Ishizuka N, Kako N. A case of sigmoid colon perforation by barium retention. *Nihon Rinsho Geka Igakkai Zasshi (J Jpn Prac Surg Soc)* 1992;53(6):1390–3 [in Japanese]. doi:10.3919/ringe1963.53.1390.

[6] Sung JP, O'Hara VS, Lee C-Y. Barium peritonitis. *Western J Med* 1977;127(2):172–6.

[7] Yamamura M, Nishi M, Furubayashi H, Hioki K, Yamamoto M. Barium peritonitis. Report of a case and review of the literature. *Dis Colon Rectum* 1985;28(5):347–52. doi:10.1007/BF02560439.

[8] Shinkawa N, Imada M, Azuma M, Shinkawa N, Yukawa N. A clear presentation of intracranial hypostasis on PMCT. *J Forensic Leg Med* 2023;97:102540. doi:10.1016/j.jflm.2023.102540.

[9] O'Donnell CJ, Baker MA. Postmortem CT findings of “gastromalacia”: a trap for the radiologist with forensic interest. *Forensic Sci Med Pathol* 2010;6(4):293–7. doi:10.1007/s12024-010-9160-2.

[10] Levy AD, Harcke HT, Mallak CT. Postmortem imaging: MDCT features of postmortem change and decomposition. *Am J Forensic Med Pathol* 2010;31(1):12–17. doi:10.1097/PAF.0b013e3181c65e1a.

[11] Uekita I, Ijiri I, Nagasaki Y, Haba R, Funamoto Y, Matsunaga T, et al. Medico-legal investigation of chicken fat clot in forensic cases: immunohistochemical and retrospective studies. *Leg Med* 2008;10(3):138–42. doi:10.1016/j.legalmed.2007.11.004.

[12] Sutherland T, O'Donnell C. The artefacts of death: CT post-mortem findings. *J Med Imaging Radiat Oncol* 2018;62(2):203–10. doi:10.1111/1754-9485.12691.

[13] Kasuda S, Kondo T, Tanaka N, Kudo R, Yuui K, Terazawa I, et al. An autopsy case of the sigmoid colon perforation after barium gastrography. *Forensic Pathol* 2021;27(1):61–5 [in Japanese].

[14] Akashi M, Oka Y, Sasahara H, Nagamatsu Y, Sueyoshi S, Akagi Y. A case of sigmoid colon perforation after upper gastrointestinal series. *Jpn J Clinical Experimental Med* 2018;95(9):84–8 [in Japanese].

[15] McPhedran NT. Rupture of the colon in the absence of any pathological abnormality. *Can J Surg* 1964;7:293–6.

[16] Brearley R. Spontaneous perforation of the colon due to alkaline medication. *Br Med J* 1954;1(4864):743. doi:10.1136/bmj.1.4864.743.

[17] Shin Y, Yamana I, Ichikawa J, Sannomiya H, Koreeda N, Sato K, et al. A case of colorectal perforation after barium gastrography. *J Abdom Emerg Med* 2019;39(6):1095–9 [in Japanese].